

**Consensus Recommendations for Transcranial Color-Coded Duplex Sonography for the Assessment of Intracranial Arteries in Clinical Trials on Acute Stroke**  
Max Nedelmann, Erwin Stolz, Tibo Gerriets, Ralf W. Baumgartner, Giovanni Malferrari, Guenter Seidel and Manfred Kaps

*Stroke*. 2009;40:3238-3244; originally published online August 6, 2009;  
doi: 10.1161/STROKEAHA.109.555169

*Stroke* is published by the American Heart Association, 7272 Greenville Avenue, Dallas, TX 75231  
Copyright © 2009 American Heart Association, Inc. All rights reserved.  
Print ISSN: 0039-2499. Online ISSN: 1524-4628

The online version of this article, along with updated information and services, is located on the World Wide Web at:

<http://stroke.ahajournals.org/content/40/10/3238>

**Permissions:** Requests for permissions to reproduce figures, tables, or portions of articles originally published in *Stroke* can be obtained via RightsLink, a service of the Copyright Clearance Center, not the Editorial Office. Once the online version of the published article for which permission is being requested is located, click Request Permissions in the middle column of the Web page under Services. Further information about this process is available in the [Permissions and Rights Question and Answer](#) document.

**Reprints:** Information about reprints can be found online at:  
<http://www.lww.com/reprints>

**Subscriptions:** Information about subscribing to *Stroke* is online at:  
<http://stroke.ahajournals.org/subscriptions/>

# Consensus Recommendations for Transcranial Color-Coded Duplex Sonography for the Assessment of Intracranial Arteries in Clinical Trials on Acute Stroke

Max Nedelmann, MD; Erwin Stolz, MD; Tibo Gerriets, MD; Ralf W. Baumgartner, MD; Giovanni Malferrari, MD; Guenter Seidel, MD; Manfred Kaps, MD; for the TCCS Consensus Group\*

**Background and Purpose**—Transcranial color-coded duplex sonography has become a standard diagnostic technique to assess the intracranial arterial status in acute stroke. It is increasingly used for the evaluation of prognosis and the success of revascularization in multicenter trials. The aim of this international consensus procedure was to develop recommendations on the methodology and documentation to be used for assessment of intracranial occlusion and for monitoring of recanalization.

**Methods**—Thirty-five experts participated in the consensus process. The presented recommendations were approved during a meeting of the consensus group in October 2008 in Giessen, Germany. The project was an initiative of the German Competence Network Stroke and performed under the auspices of the Neurosonology Research Group of the World Federation of Neurology.

**Results**—Recommendations are given on how examinations should be performed in the time-limited situation of acute stroke, including criteria to assess the quality of the acoustic bone window, the use of echo contrast agents, and the evaluation of intracranial vessel status. The important issues of the examiners' training and experience, the documentation, and analysis of study results are addressed. One central aspect was the development of standardized criteria for diagnosis of arterial occlusion. A transcranial color-coded duplex sonography recanalization score based on objective hemodynamic criteria is introduced (consensus on grading intracranial flow obstruction [COGIF] score).

**Conclusions**—This work presents consensus statements in an attempt to standardize the application of transcranial color-coded duplex sonography in the setting of acute stroke research, aiming to improve the reliability and reproducibility of the results of future stroke studies. (*Stroke*. 2009;40:3238-3244.)

**Key Words:** consensus ■ stroke transcranial color-coded duplex sonography ■ ultrasound

Transcranial color-coded duplex sonography (TCCS) is widely used to evaluate the intracranial arterial system in patients with acute stroke. Because it is a noninvasive real-time method, it can be used as a bedside tool to identify patients with compromised intracranial hemodynamics. Numerous studies highlight its value in diagnosis and follow-up of acute stroke patients.

By combining B-mode and color Doppler imaging, TCCS provides several advantages compared with transcranial Doppler sonography: (1) it more reliably identifies blood flow in specific intracranial vessel segments; (2) it allows a more detailed allocation of vessel pathologies; and (3) it offers the opportunity for angle correction, resulting in more accurate measurement of flow velocities. Furthermore, TCCS enables detection of the position of the third ventricle and a potential midline shift in ischemic stroke.<sup>1-3</sup> Although intra-

cerebral hemorrhage (including hemorrhagic transformation of stroke), aneurysms, and arteriovenous malformations may be detected by TCCS,<sup>4-12</sup> it is not the first-line imaging method in these situations.

TCCS is increasingly used in studies on recanalization therapies as a tool to assess occlusive disease of the main segments of the intracranial arteries, to evaluate early recanalization, and to guide therapeutic decisions.<sup>13-17</sup> Ultrasound evaluation provides important prognostic information in the acute stage of stroke.<sup>18-21</sup>

However, there is currently no systematic consensus agreement on how TCCS examination of acute stroke is best performed. Standardized recommendations are needed to increase reproducibility and comparability of the results of TCCS studies of acute stroke especially in a multicenter setting. The aim of this consensus was to give recommenda-

Received April 8, 2009; final revision received June 10, 2009; accepted June 17, 2009.

From Department of Neurology (M.N., E.S., T.G., M.K.), Justus Liebig University, Giessen, Germany; Department of Neurology (R.W.B.), University Hospital of Zurich, Zurich, Switzerland; Department of Neurology (G.M.), Arcispedale S. Maria Nuova, Reggio Emilia, Italy; Department of Neurology (G.S.), University Hospital Schleswig-Holstein, Campus Luebeck, Germany.

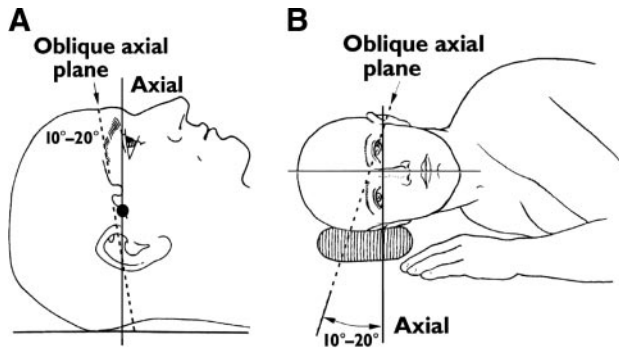
\*The members of the TCCS consensus group are listed in the Appendix.

Correspondence to Max Nedelmann, MD, Department of Neurology, Justus Liebig University Giessen, Am Steg 14, 35385 Giessen, Germany. E-mail max.nedelmann@neuro.med.uni-giessen.de

© 2009 American Heart Association, Inc.

Stroke is available at <http://stroke.ahajournals.org>

DOI: 10.1161/STROKEAHA.109.555169



**Figure 1.** Sketch showing head and planes commonly used in transcranial color-coded duplex sonography. A, Sonographic plane (dashed line) is skewed anteroposteriorly by 10° to 20° from anatomic axial plane (solid line) by rotating transducer slightly toward occiput. ●Position of probe. B, Sonographic plane (dashed line) is also angled in frontal projection by ≈ 10° to 20° from standard axial plane (solid line) by tilting transducer caudally (back relative to front) ≈ 10° to 20°. Reproduced with permission from Krejza et al.<sup>24</sup>

tions on a standardized approach to utilize TCCS in multi-center acute stroke studies.

For the consensus process, the “state-of-the-art” approach developed by Glaser<sup>22</sup> was chosen. A group of experts prepared a draft manuscript based on a systematic review of the literature on TCCS in acute stroke by an extensive search in electronic databases and hand-searching key journals.

In the second step, this draft was sent to a group of 35 international experts invited to participate in the consensus process. The experts were identified and selected on basis of previous publications in the field of TCCS in acute stroke.

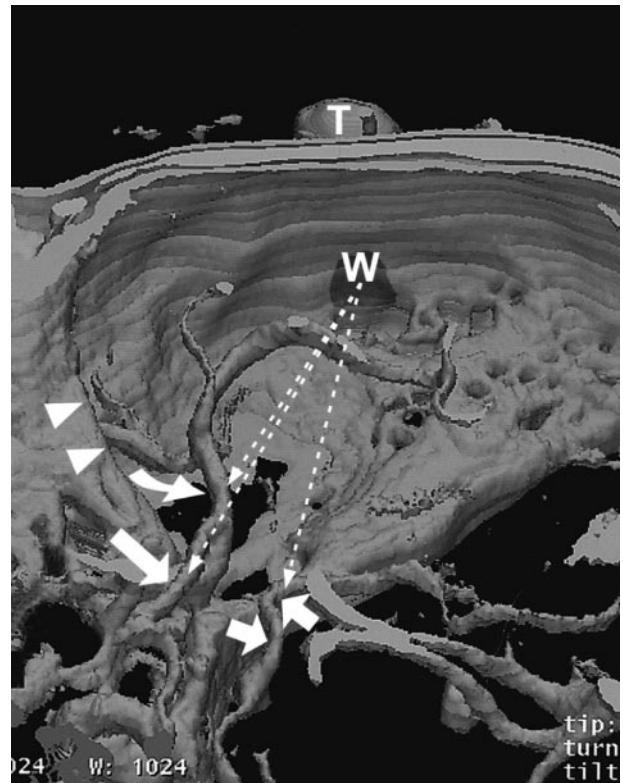
After the receipt of the participants’ suggestions, a revised version of the manuscript was prepared and discussed in a consensus meeting in October 2008 in Giessen, Germany. All participants of the consensus group approved the recommendations presented in this work.

## How to Measure

### Examination Procedure

Even though no formal consensus on the examination plane used for TCCS examinations has yet been developed, because in principle the examination plane can be chosen freely within the acoustic window, it is common standard to apply an axial mesencephalic insonation plane through the temporal bone window, allowing the depiction of the circle of Willis.<sup>20–23</sup> This plane is essentially characterized by the butterfly-shape mesencephalic brain stem on B-mode imaging and by depiction of basal cerebral vessels in the color mode. Because of different angles, the axial insonation plane is usually not identical to the axial plane displayed with MR and CT imaging (Figures 1 and 2). The lesser sphenoid wing serves as a B-mode landmark for the terminal internal carotid artery (ICA) and the siphon.

The main branches of the circle of Willis (ie, sphenoidal [M1] and insular [M2] segments of the middle cerebral artery [MCA], precommunicating [A1] segment of the anterior cerebral artery [ACA], distal intracranial part of the ICA, and precommunicating [P1] and postcommunicating [P2] segments of the posterior cerebral artery [PCA]) can be recog-



**Figure 2.** Three-dimensional CT reconstruction shows course of ultrasound beam (dashed arrows) toward middle (curved arrow), anterior (long straight arrow), and posterior (short straight arrows) cerebral arteries. Note resultant sites of vessel intersection with ultrasound beam and angle of insonation, as well as relationship of arteries to lesser sphenoid wing (arrowheads), acoustic window (W), and transducer. T = transducer. Reproduced with permission from Krejza et al.<sup>24</sup>

nized and allocated in the color-coded B-mode image. In case of difficulties in differentiation of arterial segments and localization of pathological findings, an additional examination in the coronal plane may be helpful.<sup>23</sup> The entire course of all large arteries, as well as all pathological findings, has to be investigated by color-coded as well as spectral Doppler sonography. The depiction of B-mode structures, in combination with the superimposed color-coded flow-velocity map, should be used for the evaluation of the quality of the acoustic bone window.<sup>24</sup> The color-coded flow-velocity map serves as an examination tool for the presence of stenoses, occlusions, and collateral flow through the circle of Willis. For details on the examination procedure, the clinical application, and normal values, reference is made to recent reviews.<sup>25–27</sup>

### Consensus Statement 1

An adequate interpretation of intracranial findings always requires careful assessment of the extracranial vasculature, because obstructive disease of extracranial vessels may significantly influence or severely compromise intracranial hemodynamics.

### Consensus Statement 2

The standard extracranial protocol in the acute stroke setting does not necessarily include evaluation of the ophthalmic artery or supraorbital arteries. In case of relevant ICA

pathology, an inverted flow direction in the ophthalmic artery does not provide further information beyond a complete ICA examination. In case of insufficient temporal bone window, evaluation of ophthalmic artery flow direction may be of additional value.

### Acoustic Window

The main limitation of TCCS arises from poor acoustic insonation conditions. Because of an insufficient temporal bone acoustic window, insonation of the basal cerebral arteries is incomplete in  $\approx 10\%$  of patients with cerebrovascular diseases.<sup>28–30</sup> Application of an ultrasound contrast agent increases the number of conclusive ultrasound studies and allows adequate diagnosis in  $\approx 80\%$  to  $90\%$  of those patients with insufficient bone windows.<sup>31–38</sup>

A sufficient bone window can be assumed once the ipsilateral proximal branches of the circle of Willis can be displayed, including sufficient Doppler spectra. For the situation of carotid T-occlusion, please refer to the respective section.

### Consensus Statement 3

Ultrasound contrast agents (UCA) should be used in the setting of clinical trials:

- In case of an insufficient temporal acoustic bone window: insufficient signal intensity, or absent visibility of the proximal branches of the circle of Willis.
- In cases in which UCA are given at baseline, follow-up examinations should also be performed with UCA. This is important because measured flow velocities may be higher when using UCA.<sup>34,39</sup>
- Because of varying availability of UCA in different countries and because of a lack of studies with direct comparison of the different UCA, there are no specific recommendations on the type of UCA. In view of the current literature, application of multiple small boli or continuous intravenous infusion increases the length of the diagnostically useful time window.

### Angle Correction

One of the advantages of TCCS over transcranial Doppler sonography is the use of angle-corrected flow velocity measurements. Because of anatomic variations, the angle between the transtemporally transmitted ultrasound beam and the major intracranial arteries varies considerably between different arterial segments, between similar segments of different individuals, and interhemispherically within the same person.<sup>40</sup> Angle correction reduces the inaccuracy in flow velocity measurements and allows defining diagnostic criteria with a higher sensitivity to detect intracranial arterial narrowing (ie, stenosis, vasospasm).<sup>41–43</sup> Angle corrected measurements do not decrease intrarater or interrater reproducibility as compared to noncorrected measurements.<sup>44–47</sup>

### Consensus Statement 4

To prevent inadequate measurements, angle correction should only be applied to velocity measurements when the sample volume can be located in a sufficiently long vessel segment that allows sufficient tracing of the main flow vector.<sup>25,48</sup> In case of a stenosis being located in a curved arterial

segment, angle correction should be omitted, and the ultrasound probe should be repositioned to obtain the smallest insonation angle possible.

### Consensus Statement 5

In case of angle-corrected measurements, the correction angle or additional values of uncorrected velocities (that can be calculated from angle corrected velocities and the correction angle) should be provided in publications. This may help to further define the value of angle correction.

Angle correction potentially is of great value for the evaluation of flow velocity differences between both MCA. Asymmetry of flow velocities is an important indirect criterion for the diagnosis of MCA stenoses. Most importantly, because branch occlusions of the MCA cannot reliably be depicted directly, the indirect diagnosis of branch occlusions relies on a reduction of the M1 flow velocity compared to the contralateral side. A prospective, angiography-controlled study defined nonangle-corrected Doppler criteria for the detection of branch occlusions. An asymmetry index is defined that helps to differentiate normal flow velocities from reduced M1 flow in multiple ( $\geq 3$ ) branch occlusions (asymmetry index).<sup>49</sup>

Another angiography-controlled study established angle-corrected, contrast-enhanced TCCS criteria for MCA branch occlusion. An end-diastolic velocity within the M1 segment of  $< 26$  cm/sec in combination with an end-diastolic ratio of  $< 2.5$  between the contralateral and the ipsilateral M1 segments identified branch occlusion (as opposed to  $> 2.5$  indicating M1 occlusion).<sup>50</sup> However, this study was small and no specifications were made on how the criteria relate to the number of affected MCA branches. Furthermore, peak velocities assessed with contrast-enhanced TCCS are  $\approx 10\%$  to  $20\%$  higher compared to those assessed without echo contrast agents.<sup>34,39</sup> It is thus possible that only the criterion “end-diastolic ratio  $< 2.5$ ,” but not the criterion “end-diastolic MCA velocity  $< 26$  cm/sec” is useful for nonenhanced TCCS.


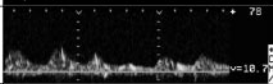
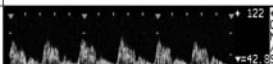


### Consensus Statement 6

To date, 2 studies have been published that investigated hemodynamics of the M1 segment in MCA branch occlusion. Its solid evaluation requires normal extracranial and contralateral findings as a prerequisite. Angle-corrected TCCS may allow a more accurate approach to detection of MCA branch occlusion. However, the studies discussed were small and one of them used contrast-enhanced TCCS. Therefore, no recommendation can be made regarding which of the criteria should be used in the setting of clinical trials until validation of this specific issue is conducted in a larger study.

In the presence of a large brain lesion (ischemic or hemorrhagic), tissue edema may dynamically expand and modify the MCA course in the first hours and days after stroke onset.<sup>51</sup> The resulting change of the insonation angle on the affected side may possibly lead to misinterpretations in comparison to the contralateral, unaffected side. Correction of the insonation angle in space occupying stroke has not been studied so far.

### What to Measure

In single and multicenter transcranial Doppler sonography studies, the thrombolysis in brain ischemia (TIBI) score has

COGIF grade	Hemodynamic pattern	Example
1	No flow	
2	Low flow velocities without diastolic flow	
3	Low flow velocities with diastolic flow	
4	Established perfusion:	
	a) flow velocities equal to contralateral side	
	b) high focal flow velocities (i.e. stenosis)	
c) high segmental flow velocities (hyperperfusion)		

**Figure 3.** COGIF score for assessment of baseline findings before thrombolysis and changes during the recanalization process.

been widely used for the assessment of initial hemodynamics and recanalization phenomena.<sup>52–54</sup> This scale comprises 6 different degrees of hemodynamic abnormalities. In practice, the application of these degrees is difficult and in part quite subjective. Therefore, flow grades are frequently separated into 3 major categories.<sup>55</sup> MCA main stem occlusion (TIBI 0–1), partial recanalization (TIBI 2–3), and complete recanalization (TIBI 4–5) are assigned to these categories. These 3 categories have been externally validated by angiography. However, only approximately half the cases were evaluated by conventional angiography, and the time interval between Doppler and angiography studies was long.<sup>55</sup>

Differentiation of TIBI grades 1 to 3 (minimal flow, blunted flow, dampened flow) is especially difficult. Furthermore, flow patterns of these grades not only reflect partial recanalization of the M1 but also include different hemodynamic situations in upstream and downstream stenosis and occlusion (including obstruction of the ICA [upstream] and obstruction of MCA branches [downstream]).

Therefore, we aimed at translating the TIBI score into a TCCS-based grading system (consensus on grading intracranial flow obstruction [COGIF] score). This scoring system is exclusively based on known hemodynamic changes of the Doppler spectrum that can be observed in the acute stage of stroke. This tool can be applied for both baseline evaluation and assessment of the recanalization progress during follow-up (Figure 3, Table). The major grades of the COGIF score comprise vessel occlusion (grade 1), partial recanalization (grades 2 and 3), and established perfusion (grade 4).

#### Comment on COGIF Grade 1: No Flow

This corresponds to the sonographic finding seen in occlusion of the M1 segment of the MCA or the carotid T.

#### Occlusion of the M1 Segment (MCA Main Stem Occlusion)

The main diagnostic criterion of the occlusion of the M1 segment is the absence of a color Doppler flow signal and its Doppler spectrum in the location of the proximal MCA

**Table.** Possible Hemodynamic Alterations of Follow-Up Findings in Relation to the Vascular Situation at Baseline

Hemodynamic Alteration	Effect on COGIF Score
1. Reflow	
A. Partial recanalization	Improvement by $\geq 1$ grade
B. Complete recanalization	Improvement to grade 4
2. No change	Baseline COGIF grade persists
3. Worsening	Deterioration by $\geq 1$ grade

Also see Figure 3.

segment.<sup>29,56–58</sup> Because the absence of Doppler signals may be a consequence of an insufficient acoustic bone window, a reliable diagnosis of arterial occlusion requires a sufficient visibility of the other arteries (ACA A1-segment, C1-segment of intracranial ICA) or veins (deep middle cerebral vein) of the anterior circulation or visibility of the contralateral anterior circulation.

#### Carotid T Occlusion

TCCS lacks angiographically validated criteria for the diagnosis of carotid T occlusion. The mostly used diagnostic criterion of carotid T occlusion is the absence of color Doppler flow signal and its Doppler spectrum in the M1 segment of the MCA, the intracranial ICA, and the ipsilateral A1 segment of the ACA. Good visibility of the deep middle cerebral vein, the ipsilateral A2 segment, or the contralateral anterior circulation increases the reliability of this diagnosis.

#### Consensus Statement 7

If these criteria are fulfilled, it is not necessary to further confirm these diagnoses by use of UCA. A minimal quality standard requires the use of UCA only if insonation conditions are unsatisfactory and a reliable diagnosis is not possible otherwise (see Consensus Statement 3).

#### Consensus Statement 8

Diagnosis of a carotid T occlusion should be additionally confirmed by presence of decreased flow velocities, in particular end-diastolic, or oscillating flow, in the ipsilateral cervical ICA and common carotid artery in comparison to the contralateral side.

#### Comment on Grades 2 and 3: Low Flow

This situation may be caused by different pathological conditions. Low-flow phenomena in the M1 segment of the MCA may be found in the situation of a partial recanalization of the M1 segment or the carotid T, and also in case of an upstream carotid obstruction, or in case of a downstream obstruction (ie, distal main stem or MCA branch occlusions). Upstream or downstream obstruction has to be differentiated from partial recanalization of the M1.

#### Upstream Obstruction

A hemodynamically compromising ICA lesion can reduce downstream flow velocities in the MCA without MCA or intracranial ICA disease. Such a lesion can also produce compensatory increased flow velocities in the contralateral hemisphere, thereby increasing the asymmetry index.<sup>41,59</sup> To ascribe an intracranial flow reduction to intracranial pathology, an upstream obstruction of the ICA has to be ruled out.

**Downstream Obstruction (Branch Occlusions)**

The diagnosis of MCA branch occlusions is based on the calculation of the asymmetry index (see Angle Correction). This index should only be calculated if the supplying carotid arteries and the contralateral MCA can be assessed without relevant stenosis or occlusion.

In the COGIF score, low-flow velocities without diastolic flow, indicating a state of residual flow, are distinguished from complete obstruction, because residual flow signals are associated with improved results of tissue plasminogen activator thrombolysis.<sup>60,61</sup>

**Comment on Grade 4: Established Perfusion**

In this grade, different hemodynamic situations are integrated, including normal flow (4a), stenotic flow (4b), and high-flow velocities in hyperperfusion (4c). This was performed because the consensus group thought that delineation of high-flow velocities from normal-flow velocities is less relevant in consideration of the foremost goal of acute stroke treatment, the reestablishment of sufficient hemispheric perfusion.

This grade therefore comprises 2 different pathological conditions. A focal increase in velocity indicates intracranial stenosis, whereas increased flow velocities along a complete arterial segment reflect hyperperfusion and may be found in the initial state after recanalization, or in case of collateral flow across the involved artery.

**Consensus Statement 9**

In a prospective study, TCCS data were correlated with digital subtraction angiography.<sup>41</sup> Criteria based on this study allowed for the reliable assessment of  $\geq 50\%$  and  $< 50\%$  basal cerebral artery diameter narrowing. They should be applied for the detection and follow-up of intracranial stenoses. However, these criteria have not been validated in the setting of acute stroke. Reactive hyperperfusion may possibly lead to overestimation of the degree of intracranial stenosis.

**Follow-Up Evaluation (Recanalization)**

Follow-up evaluation is an important issue in TCCS studies. A standardized and uniformly used recanalization protocol will strongly improve the comparability of different studies.

The time point of a suitable follow-up evaluation cannot be generally recommended and has to be part of the protocol of every individual study. It has to be taken into consideration that the hemodynamic situation in the acute phase of vessel occlusion and during the recanalization progress is subject to fluctuations. To prevent incorrect interpretations, the time points of the follow-up evaluations should be well-standardized within a study protocol and adhered to in all individual study subjects. Furthermore, care has to be taken to perform follow-up measurements at exactly the same localization that was chosen at baseline (as defined by insonation depth and angle correction).

Possible hemodynamic alterations of follow-up findings in relation to the vascular situation at baseline are: (1) reflow (partial or complete recanalization); (2) no change; and (3) worsening (Table).

**Comment on 1: Reflow**

Partial recanalization is assumed in case of:

- Improvement by  $\geq 1$  grades on the COGIF score.

Complete recanalization is assumed, if:

- Flow within the previously occluded vessel has developed to grade 4.

**Comment on 2: No Change**

No change is assumed, if:

- The COGIF grade from baseline evaluation persists.

**Comment on 3: Worsening**

Worsening is assumed, if:

- The flow situation deteriorates by  $\geq 1$  grades on the COGIF score.

**Who Examines the Patients and How to Document the Findings**

The quality of sonographic study results directly depends on the skills and experience of the examiner. All ultrasound procedures in clinical trials therefore need to be performed by sufficiently trained and experienced sonographers. The organizers of clinical trials should define minimum quality requirements for their participating sonographers before patient recruitment. The consensus group agreed that an international quality guideline developed by the Neurosonology Research Group should serve as a basis for elaborating standards for individual trials ([www.nsr.org.tw/expert.htm](http://www.nsr.org.tw/expert.htm)).

**Consensus Statement 10**

The ultrasound findings should be interpreted on site by an experienced ultrasound investigator. Subsequent offline analysis of recorded videotapes, prints, or digitally stored screenshots has proven to be less reliable in previous studies. Because of a lack of reliable data on the optimal way of study documentation, further research in this field is necessary.

**Consensus Statement 11**

Because full blinding of the ultrasound investigator is not feasible, follow-up clinical assessment should be blinded with respect to the ultrasound findings. In case of treatment studies, the ultrasound investigator should not be aware of the treatment allocation.

All extracranial and transcranial sonographic findings should be documented according to established guidelines (an English version of the recommendations for documentation of the German Society of Ultrasound in Medicine is available online at [www.degum.de/657.html](http://www.degum.de/657.html)). In case of unaffected vessels, this includes documentation of both color imaging and Doppler spectra. In case of pathological findings, documentation includes recording of the pathology and of the vessel segments upstream and downstream to the focus. Each pathological finding has to be documented separately in such a way that the interpretation of the initial examiner is comprehensible.

**Concluding Remarks**

This work presents consensus statements based on the experience of a panel of experts in an attempt to standardize the methodology for TCCS in the setting of acute stroke research,

aiming to improve the reliability and reproducibility of the results of future stroke studies. The consensus statements cover different aspects of TCCS application the consensus panel thought to be controversial and that need clarification for more uniform use of this diagnostic modality.

The presented COGIF score may serve as a tool to more reliably assess vascular status and treatment results in case of acute intracranial vessel occlusion. We aimed to design this score to evaluate hemodynamic alterations that can be objectively recognized and categorized. Proper use of the score requires careful assessment of all brain supplying arteries to rule out indirect effects by upstream and downstream vascular obstructions possibly influencing the hemodynamics of the target vessel. Based on this prerequisite, the score may improve comparability of study results. However, it is stressed that this score has not yet been validated against another imaging modality.

## Appendix

### The TCCS Consensus Group

Anita Arsovska (Skopje, Macedonia), Eva Bartels (Muenchen, Germany), Ralf Baumgartner (Zurich, Switzerland), Dirk Droste (Muenster, Germany), Juergen Eggers (Hamburg, Germany), Jens Eyding (Bochum, Germany), Georg Gahn (Karlsruhe, Germany), Dimitrios Georgiadis (Zurich, Switzerland), Tibo Gerriets (Giessen, Germany), Michael Goertler (Magdeburg, Germany), Hajo Hamer (Marburg, Germany), Arjan W. Hoksbergen (Amsterdam, Netherlands), Manfred Kaps (Giessen, Germany), Christof Kloetzsch (Allensbach, Germany), Grzegorz Kozaera (Gdansk, Poland), Jaroslaw Krejza (Philadelphia, USA), Vincent Larrue (Toulouse, France), Giovanni Malferrari (Reggio Emilia, Italy), Mathias Maeurer (Erlangen, Germany), Kazuo Minematsu (Osaka, Japan), Max Nedelmann (Giessen, Germany), Fabienne Perren (Geneva, Switzerland), Thomas Postert (Paderborn, Germany), E. Bernd Ringelstein (Muenster, Germany), Martin Ritter (Muenster, Germany), Felix Schlachetzki (Regensburg, Germany), Eberhard Schmitt (Koblenz, Germany), Guenter Seidel (Luebeck, Germany), David Skoloudik (Olomouc, Czech Republic), Erwin Stolz (Giessen, Germany), Roman Sztajzel (Geneva, Switzerland), Charles Tegeler (Winston-Salem, USA), Gerhard-Michael von Reutern (Bad Salzhausen, Germany), Joanna Wardlaw (Edinburgh, United Kingdom), and Michael Wunderlich (Magdeburg, Germany).

### Sources of Funding

This work has been supported by a grant from the German Competence Network Stroke.

### Disclosure

None.

### References

- Gerriets T, Stolz E, Modrau B, Fiss I, Seidel G, Kaps M. Sonographic monitoring of midline shift in hemispheric infarctions. *Neurology*. 1999; 52:45–49.
- Seidel G, Gerriets T, Kaps M, Missler U. Dislocation of the third ventricle due to space-occupying stroke evaluated by transcranial duplex sonography. *J Neuroimaging*. 1996;6:227–230.
- Stolz E, Gerriets T, Fiss I, Babacan SS, Seidel G, Kaps M. Comparison of transcranial color-coded duplex sonography and cranial CT measurements for determining third ventricle midline shift in space-occupying stroke. *Am J Neuroradiol*. 1999;20:1567–1571.
- Becker G, Winkler J, Hofmann E, Bogdahn U. Differentiation between ischemic and hemorrhagic stroke by transcranial color-coded real-time sonography. *J Neuroimaging*. 1993;3:41–47.

- Seidel G, Kaps M, Dorndorf W. Transcranial color-coded duplex sonography of intracerebral hematomas in adults. *Stroke*. 1993;24: 1519–1527.
- Maurer M, Shambal S, Berg D, Woydt M, Hofmann E, Georgiadis D, Lindner A, Becker G. Differentiation between intracerebral hemorrhage and ischemic stroke by transcranial color-coded duplex-sonography. *Stroke*. 1998;29:2563–2567.
- Baumgartner RW, Mattle HP, Schroth G. Transcranial colour-coded duplex sonography of cerebral arteriovenous malformations. *Neuroradiology*. 1996; 38:734–737.
- Fischer B, Klotzsch C, Nahser HC, Henkes H, Kuhne D, Berlit P. [clinical application of transcranial color-coded duplex ultrasound for detection of intracranial aneurysms]. *Nervenarzt*. 1998;69:671–677.
- Griewing B, Motsch L, Piek J, Schminke U, Brassel F, Kessler C. Transcranial power mode Doppler duplex sonography of intracranial aneurysms. *J Neuroimaging*. 1998;8:155–158.
- Klotzsch C, Bozzato A, Lammers G, Mull M, Lennartz B, Noth J. Three-dimensional transcranial color-coded sonography of cerebral aneurysms. *Stroke*. 1999;30:2285–2290.
- Seidel G, Cangur H, Albers T, Meyer-Wiethe K. Transcranial sonographic monitoring of hemorrhagic transformation in patients with acute middle cerebral artery infarction. *J Neuroimaging*. 2005;15:326–330.
- Perren F, Horn P, Kern R, Bueltmann E, Hennerici M, Meairs S. A rapid noninvasive method to visualize ruptured aneurysms in the emergency room: three-dimensional power Doppler imaging. *J Neurosurg*. 2004; 100:619–622.
- Gerriets T, Goertler M, Stolz E, Postert T, Sliwka U, Schlachetzki F, Seidel G, Weber S, Kaps M. Feasibility and validity of transcranial duplex sonography in patients with acute stroke. *J Neurol Neurosurg Psychiatry*. 2002;73:17–20.
- Sekoranta L, Loulidi J, Yilmaz H, Lovblad K, Temperli P, Comelli M, Sztajzel RF. Intravenous versus combined (intravenous and intra-arterial) thrombolysis in acute ischemic stroke: A transcranial color-coded duplex sonography-guided pilot study. *Stroke*. 2006;37:1805–1809.
- Wunderlich MT, Stolz E, Seidel G, Postert T, Gahn G, Sliwka U, Goertler M. Conservative medical treatment and intravenous thrombolysis in acute stroke from carotid T occlusion. *Cerebrovasc Dis*. 2005;20:355–361.
- Perren F, Loulidi J, Graves R, Yilmaz H, Rufenacht D, Landis T, Sztajzel R. Combined iv-intra-arterial thrombolysis: a color-coded duplex pilot study. *Neurology*. 2006;67:324–326.
- Ringelstein EB, Biniek R, Weiller C, Ammeling B, Nolte PN, Thron A. Type and extent of hemispheric brain infarctions and clinical outcome in early and delayed middle cerebral artery recanalization. *Neurology*. 1992; 42:289–298.
- Allendoerfer J, Goertler M, von Reutern GM. Prognostic relevance of ultra-early doppler sonography in acute ischaemic stroke: a prospective multicentre study. *Lancet Neurol*. 2006;5:835–840.
- Wunderlich MT, Goertler M, Postert T, Schmitt E, Seidel G, Gahn G, Samii C, Stolz E. Recanalization after intravenous thrombolysis: does a recanalization time window exist? *Neurology*. 2007;68:1364–1368.
- Malferrari G, Bertolino C, Casoni F, Zini A, Sarra VM, Sanguigni S, Pratesi M, Lochner P, Coppo L, Brusa G, Guidetti D, Cavuto S, Marcello N. The ELIGIBLE study: ultrasound assessment in acute ischemic stroke within 3 hours. *Cerebrovasc Dis*. 2007;24:469–476.
- Wong KS, Li H. Long-term mortality and recurrent stroke risk among Chinese stroke patients with predominant intracranial atherosclerosis. *Stroke*. 2003;34:2361–2366.
- Glaser EM. Using behavioral science strategies for defining the state-of-the-art. *J Applied Behav Sci*. 1980;16:79–92.
- Valaikiene J, Schuierer G, Ziemus B, Dietrich J, Bogdahn U, Schlachetzki F. Transcranial color-coded duplex sonography for detection of distal internal carotid artery stenosis. *Am J Neuroradiol*. 2008;29: 347–353.
- Krejza J, Mariak Z, Melhem ER, Bert RJ. A guide to the identification of major cerebral arteries with transcranial color Doppler sonography. *AJR Am J Roentgenol*. 2000;174:1297–1303.
- Zipper SG, Stolz E. Clinical application of transcranial colour-coded duplex sonography—a review. *Eur J Neurol*. 2002;9:1–8.
- Baumgartner RW. Transcranial color duplex sonography in cerebrovascular disease: a systematic review. *Cerebrovasc Dis*. 2003;16:4–13.
- Krejza J, Baumgartner RW. Clinical applications of transcranial color-coded duplex sonography. *J Neuroimaging*. 2004;14:215–225.
- Seidel G, Kaps M, Gerriets T. Potential and limitations of transcranial color-coded sonography in stroke patients. *Stroke*. 1995;26:2061–2066.

29. Kenton AR, Martin PJ, Abbott RJ, Moody AR. Comparison of transcranial color-coded sonography and magnetic resonance angiography in acute stroke. *Stroke*. 1997;28:1601–1606.
30. Krejza J, Swiat M, Pawlak MA, Oszkis G, Weigele J, Hurst RW, Kasner S. Suitability of temporal bone acoustic window: conventional tcd versus transcranial color-coded duplex sonography. *J Neuroimaging*. 2007;17:311–314.
31. Zunker P, Wilms H, Brossmann J, Georgiadis D, Weber S, Deuschl G. Echo contrast-enhanced transcranial ultrasound: frequency of use, diagnostic benefit, and validity of results compared with MRA. *Stroke*. 2002;33:2600–2603.
32. Postert T, Braun B, Meves S, Koster O, Przuntek H, Weber S, Buttner T. Contrast-enhanced transcranial color-coded sonography in acute hemispheric brain infarction. *Stroke*. 1999;30:1819–1826.
33. Gerriets T, Seidel G, Fiss I, Modrau B, Kaps M. Contrast-enhanced transcranial color-coded duplex sonography: efficiency and validity. *Neurology*. 1999;52:1133–1137.
34. Baumgartner RW, Arnold M, Gonner F, Staikow I, Herrmann C, Rivoir A, Muri RM. Contrast-enhanced transcranial color-coded duplex sonography in ischemic cerebrovascular disease. *Stroke*. 1997;28:2473–2478.
35. Bogdahn U, Becker G, Schliefl R, Reddig J, Hassel W. Contrast-enhanced transcranial color-coded real-time sonography: results of a phase-two study. *Stroke*. 1993;24:676–684.
36. Goertler M, Kross R, Baeumer M, Jost S, Grote R, Weber S, Wallesch CW. Diagnostic impact and prognostic relevance of early contrast-enhanced transcranial color-coded duplex sonography in acute stroke. *Stroke*. 1998;29:955–962.
37. Nabavi DG, Droste DW, Kemeny V, Schulte-Altendorneburg G, Weber S, Ringelstein EB. Potential and limitations of echocontrast-enhanced ultrasonography in acute stroke patients: a pilot study. *Stroke*. 1998;29:949–954.
38. Kunz A, Hahn G, Mucha D, Muller A, Barrett KM, von Kummer R, Gahn G. Echo-enhanced transcranial color-coded duplex sonography in the diagnosis of cerebrovascular events: a validation study. *Am J Neuroradiol*. 2006;27:2122–2127.
39. Khan HG, Gailloud P, Bude RO, Martin JB, Szopinski KT, Khaw C, Rufenacht DA, Murphy KJ. The effect of contrast material on transcranial Doppler evaluation of normal middle cerebral artery peak systolic velocity. *Am J Neuroradiol*. 2000;21:386–390.
40. Eicke BM, Tegeler CH, Dalley G, Myers LG. Angle correction in transcranial Doppler sonography. *J Neuroimaging*. 1994;4:29–33.
41. Baumgartner RW, Mattle HP, Schroth G. Assessment of  $\geq 50\%$  and  $< 50\%$  intracranial stenoses by transcranial color-coded duplex sonography. *Stroke*. 1999;30:87–92.
42. de Bray JM, Joseph PA, Jeanvoine H, Maugin D, Dauzat M, Plassard F. Transcranial Doppler evaluation of middle cerebral artery stenosis. *J Ultrasound Med*. 1988;7:611–616.
43. Ley-Pozo J, Ringelstein EB. Noninvasive detection of occlusive disease of the carotid siphon and middle cerebral artery. *Ann Neurol*. 1990;28:640–647.
44. Baumgartner RW, Mathis J, Sturzenegger M, Mattle HP. A validation study on the intraobserver reproducibility of transcranial color-coded duplex sonography velocity measurements. *Ultrasound Med Biol*. 1994;20:233–237.
45. Maeda H, Etani H, Handa N, Tagaya M, Oku N, Kim BH, Naka M, Kinoshita N, Nukada T, Fukunaga R. A validation study on the reproducibility of transcranial Doppler velocimetry. *Ultrasound Med Biol*. 1990;16:9–14.
46. Stolz E, Babacan SS, Bodeker RH, Gerriets T, Kaps M. Interobserver and intraobserver reliability of venous transcranial color-coded flow velocity measurements. *J Neuroimaging*. 2001;11:385–392.
47. Totaro R, Marini C, Cannarsa C, Prencipe M. Reproducibility of transcranial Doppler sonography: a validation study. *Ultrasound Med Biol*. 1992;18:173–177.
48. Giller CA. Is angle correction correct? *J Neuroimaging*. 1994;4:51–52.
49. Zanette EM, Fieschi C, Bozzao L, Roberti C, Toni D, Argentino C, Lenzi GL. Comparison of cerebral angiography and transcranial Doppler sonography in acute stroke. *Stroke*. 1989;20:899–903.
50. Ogata T, Kimura K, Nakajima M, Naritomi H, Minematsu K. Diagnosis of middle cerebral artery occlusive lesions with contrast-enhanced transcranial color-coded real-time sonography in acute stroke. *Neuroradiology*. 2005;47:256–262.
51. Krejza J, Mariak Z, Babikian VL. Importance of angle correction in the measurement of blood flow velocity with transcranial Doppler sonography. *Am J Neuroradiol*. 2001;22:1743–1747.
52. Alexandrov AV, Wojner AW, Grotta JC. CLOTBUST: Design of a randomized trial of ultrasound-enhanced thrombolysis for acute ischemic stroke. *J Neuroimaging*. 2004;14:108–112.
53. Demchuk AM, Burgin WS, Christou I, Felberg RA, Barber PA, Hill MD, Alexandrov AV. Thrombolysis in brain ischemia (TIBI) transcranial Doppler flow grades predict clinical severity, early recovery, and mortality in patients treated with intravenous tissue plasminogen activator. *Stroke*. 2001;32:89–93.
54. Molina CA, Ribo M, Rubiera M, Montaner J, Santamarina E, Delgado-Mederos R, Arenillas JF, Huertas R, Purroy F, Delgado P, Alvarez-Sabin J. Microbubble administration accelerates clot lysis during continuous 2-MHz ultrasound monitoring in stroke patients treated with intravenous tissue plasminogen activator. *Stroke*. 2006;37:425–429.
55. Burgin WS, Malkoff M, Felberg RA, Demchuk AM, Christou I, Grotta JC, Alexandrov AV. Transcranial Doppler ultrasound criteria for recanalization after thrombolysis for middle cerebral artery stroke. *Stroke*. 2000;31:1128–1132.
56. Gerriets T, Postert T, Goertler M, Stolz E, Schlachetzki F, Sliwka U, Seidel G, Weber S, Kaps M. DIAS I: Duplex-sonographic assessment of the cerebrovascular status in acute stroke. A useful tool for future stroke trials. *Stroke*. 2000;31:2342–2345.
57. Gahn G, Gerber J, Hallmeyer S, Hahn G, Ackerman RH, Reichmann H, von Kummer R. Contrast-enhanced transcranial color-coded duplex sonography in stroke patients with limited bone windows. *Am J Neuroradiol*. 2000;21:509–514.
58. Eggers J, Konig IR, Koch B, Handler G, Seidel G. Sonothrombolysis with transcranial color-coded sonography and recombinant tissue-type plasminogen activator in acute middle cerebral artery main stem occlusion: Results from a randomized study. *Stroke*. 2008;39:1470–1475.
59. Gortler M, Niethammer R, Widder B. Differentiating subtotal carotid artery stenoses from occlusions by colour-coded duplex sonography. *J Neurol*. 1994;241:301–305.
60. Labiche LA, Malkoff M, Alexandrov AV. Residual flow signals predict complete recanalization in stroke patients treated with tPA. *J Neuroimaging*. 2003;13:28–33.
61. Saqqur M, Tsvigoulis G, Molina CA, Demchuk AM, Shuaib A, Alexandrov AV. Residual flow at the site of intracranial occlusion on transcranial Doppler predicts response to intravenous thrombolysis: a multicenter study. *Cerebrovasc Dis*. 2008;27:5–12.